

*Original Research*

# Appraisal of Acute Oral LD<sub>50</sub> of Flonicamid and Ameliorative Effects of Selected Vitamins on Hepato Toxicity of Exposed Rabbits

**Muafia Shafiq<sup>1,2\*</sup>, Abdul Qadir<sup>1</sup>, Naqi Hussain<sup>1,2</sup>, Shamma Firdous<sup>2</sup>,  
Muhammad Naeem<sup>1,2</sup>, Sajid Rashid Ahmad<sup>1</sup>**

<sup>1</sup>College of Earth and Environmental Sciences, the University of the Punjab, Lahore, Pakistan

<sup>2</sup>Pakistan Council of Scientific and Industrial Research Laboratories Complex Lahore, Pakistan

*Received: 8 May 2021*

*Accepted: 25 April 2022*

## Abstract

Flonicamid is an insecticide which is frequently used in agriculture practices these days. However the excessive use of this chemical insecticide exhibit toxic effects on ecosystem as well as on mammals. Therefore, the present study was conducted to evaluate flonicamid median lethal dose which is 180 mg/kg body weight. Further, investigations involved the repeated oral administration of safe dose of flonicamid i.e 18 mg/kg body weight /day to various groups of rabbits alone, in combination with vitamin C and E for partial sub chronic study of 30 days. Significant increase ( $P<0.05$ ) in hepatic enzymes such as alanine aminotransferase, aspartate aminotransferase and alkaline phosphatase were observed whereas animal body weight, serum protein and serum albumin exhibited significant decrease ( $P<0.05$ ) in rabbits given only flonicamid. In addition, histological examination of liver tissues of treated rabbits showed alterations of hepatocytes morphology from severe level to mild depending upon type of treatment either given flonicamid only or co-administered with vitamin C/vitamin E. We conclude that supplementation of vitamin C alone and in combination with vitamin E each at 100 mg/kg body weight/day dose significantly reduces the toxicopathic effects of flonicamid in exposed rabbits and ameliorates the hepatic marker enzymes as well as histological aspects of liver tissues near the control group.

**Keywords:** flonicamid, oxidative stress, rabbits, vitamin C, hepatic marker enzymes, serum proteins, acute oral LD<sub>50</sub>

## Introduction

In modern agricultural practices, pesticides (i.e., fungicides, herbicides, insecticides, rodenticides, nematocides, etc.) are commonly used as an important management tool to enhance crop yield and reduce post-harvest losses. The excessive use of these synthetic pesticides is appeared as serious environmental problem which are posing hazardous effects on both terrestrial and aquatic ecosystems, on beneficial arthropods, as well as on human health [1, 2]. It causes various skin ailments like rashes and oedema, headache, ocular irritation and lacrimation, diarrhea, vomiting and chronic exposure may lead to cancer [2-3]. Recently, many researchers have reported that interaction of humans to pesticide for a certain time period cause the severe neurophysiological and neurobehavioral abnormalities [4]. Fonicamid is a pyridine carboxamide insecticide, has 4-trifluoromethylnicotinamide (TFNA-AM) as a major metabolic component. It actively kills a range of insects including whiteflies, thrips, planthoppers and mosquitos by disrupting their chordotonal organs which are involved in hearing and movement senses [5]. It shows aphid anti-feeding behavior by blocking the salivation and sap feeding ability leading towards the mortality through starvation. It shows no cross resistance to conventional insecticides and exhibits excellent safe profile on beneficial arthropods as well as with low toxicity to bees, birds, fish and mammals (male and female rat oral LD<sub>50</sub> is 884 mg/kg and 1785 mg/kg respectively) [6]. Fonicamid as a novel systemic insecticide appears to be first choice agropesticide with extensive uses to control a widespread variety of insect pests in wheat, peaches, apple, potatoes, cotton plantation, variety of vegetables production which are commonly used in our day to day life, for indoor plants pests and as an effective treatment of mosquitoes to control the vectors and pests of public health importance [7, 8]. However, this extensive application of fonicamid to crops may donate residues of toxic substances in the environment which ultimately affecting the human beings. Previous study on fonicamid exposure and risk assessment from tea garden to cup was showed that the potential dietary intake risk of fonicamid and its metabolites from fresh tea leaves to tea infusion were three times higher than chlorfluazuron which is a matter of great concern [9]. Similarly, Chauhan et al. [10] described the persistence and dissipation of fonicamid in/on paddy rice. They demonstrated that fonicamid residue were declined with passage of time until it reaches to 0.05 mg/kg at the time of harvest. Due to the persistence of pesticide residue on food they ultimately enter in to the body of consumer, making adverse effects after bioaccumulation.

Scientific community for a few decades has been interested in natural products having therapeutic properties to cure the body from intoxication caused by pesticides. Vitamin C and E are non enzymetic

antioxidants acting as free radical scavenger [11]. Vitamin C is abundantly distributed in cellular fluids and shielding the cell membranes from oxidative damage brought by any kind of pollutant. Vitamin E is residing mainly in the cell membranes and involves in strengthening of membrane stability [12]. Furthermore vitamin C assists the vitamin E to reappear to its active state in the cell membrane. Past researches had approved this regeneration process so the use of vitamins C along with vitamin E facilitate the better antioxidant protection in many diseases related with enhanced oxidative stress in spite of alone usage [12, 13]. It may not take such a long time in Pakistan since the country is not only facing the damages done to the health of workers and to the environment by the highly toxic pesticides that have been imported in large quantities. Pesticides are poisons and are meant to kill living creatures and hence the type of poisoning observed in the cotton fields of Multan and elsewhere is already a warning of the catastrophe lying ahead and must be heeded [14]. To best of our knowledge, this is the first scientific report to reveal the acute oral LD<sub>50</sub> of fonicamid in rabbits. Rabbits are considered as good experimental model which are closer to primates in phylogenetic tree as compared to other rodents and represent a better clinico- anatomical morphological anomalies associated with human diseases [15]. In the present study, it is aimed to utilize vitamin C and vitamin E to reduce fonicamid associated toxic effects as these naturally occurring chemicals having therapeutic values are cheaper, economical and easy to available/access.

## Materials and Methods

### Chemicals

All the chemicals including ascorbic acid (purity, 99%) used in the current study were analytical grade and purchased from Sigma Aldrich Chemical Co (St. Louis, MO, USA). Fonicamid used in this study were obtained from Shandong United Pesticide Industry Co., Ltd. China (Batch#2020072098510, purity 98.6%), vitamin E from Zhejiang Medicine Co., Ltd. China (Batch#201201906205, purity 99.2%).

### Animal Maintenance and Care

Male rabbits (*Oryctolagus cuniculus domesticus*) of age between 20-24 weeks and weight between 1.0 to 2.0 kg were purchased from UVAS, Lahore. These animals were acclimatized for one week before the start of experiment in the animal house of PCSIR under optimal conditions (temperature 22±3°C, relative humidity between 30 to 70%, 12 h light dark cycle) with free access to diet and fresh drinking water.

### Ethics Statement

In the present study, the experimental procedures and protocols conducted on animals were strictly followed according to OECD guidelines 423 and the same were approved from bioethical committee (AS & RB dated 05/10/2020) of University of the Punjab, Lahore.

### Nutritional Analysis of Feed

Commercially available Feed is given to rabbits during the complete study period was analyzed for nutritional composition including moisture, total ash, fat, protein and fiber content according to methods of AOAC [16].

### Experimental Design

The first part of experiment was based on determination of median lethal dose (LD<sub>50</sub>) of flonicamid in male albino rabbits (*O. cuniculus domesticus*) by following the method of Weil C.S. [17].

Rabbits were weighed and randomly divided in to five groups of 03 animals each. Group I served as control received only vehicle (non-fortified corn oil), distilled water and feed. Group II, III, IV and V received flonicamid dissolved in non-fortified corn oil at the concentration of 50, 100, 200 and 400 mg/kg b.w orally through feeding gavage in a single dose within

24 hours. Following formula will be used to estimate the LD<sub>50</sub> of flonicamid,

$$\text{Log LD}_{50} = \log D_a + d (f+1) \quad (1)$$

Where “Da” is the log of the lowest dose level, “d” is the log of constant ratio between doses levels, “f” is seen from table given in published paper of Weil C.S. [17].

Second part of the experiment was comprised of thirty days toxicity studies on the basis of safe concentration i.e. 1/10<sup>th</sup> of LD<sub>50</sub> which is determined in initial experiments. A total of 15 healthy rabbits were assigned randomly to five groups on the basis of various treatments. Flonicamid at the concentration of 1/10<sup>th</sup> of LD<sub>50</sub> and vitamin E at the concentration of 100 mg per mL were suspended in non-fortified corn oil separately. Vitamin C at the concentrations of 100mg per mL was prepared in distilled water. Doses of vitamin C and E were selected on the basis of previous studies [18, 19]. Group IS served as control, Group IIS, IIIS, IVS and VS received the flonicamid alone, in combination with Vitamin C only (F+ Vit. C), in combination with Vitamin E only (F+ Vit. E) and both Vitamin C and E (F+ Vit. C + Vit. E), respectively. Antioxidant solutions were given orally through feeding gavage 30 minutes prior to flonicamid oral administration. Body weight changes were noted every 10<sup>th</sup> day to adjust the treatment dose accordingly.

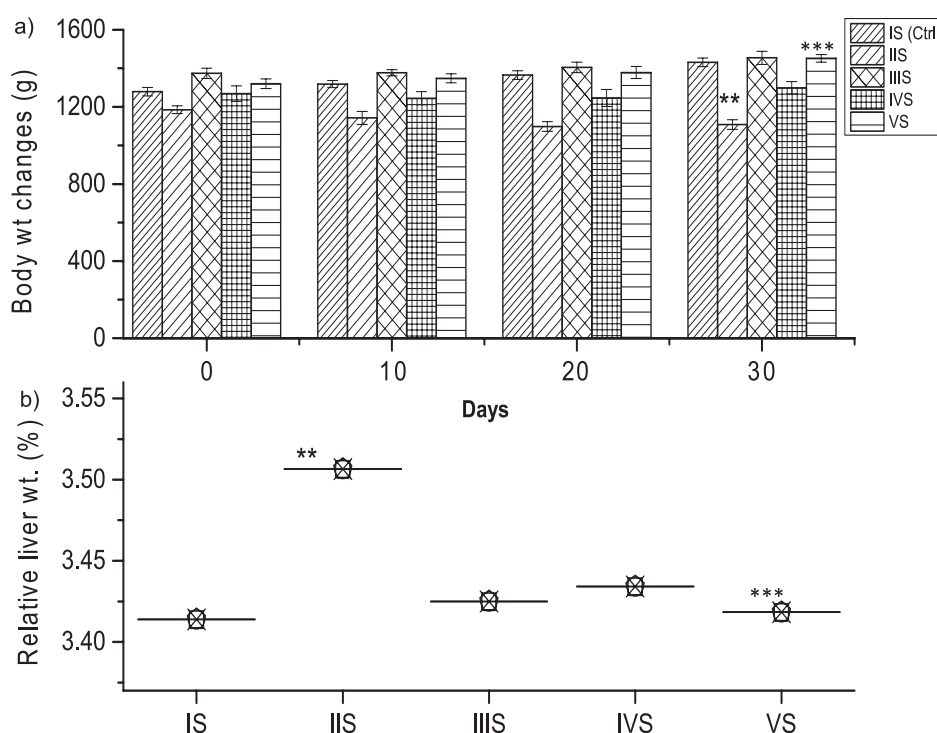


Fig. 1. Animal body changes after exposure to flonicamid and vitamins: a) Significant body weight decreased were observed in rabbits after flonicamid exposure and oral coadministration of of vitamin C & E protects the body from weight fall. b) Percent Relative liver weight gain was observed in treated rabbits as compared to control Group (IS). Values are mean±SE of five replicates. Statistically significant at P>0.05. \* Significant from control. \*\* Highly significant from control. \*\*\* Highly significant from IIS group.

### Blood and Tissue Sampling

Blood was collected from the ear vein of rabbit at starting (zero day) and then after every 15<sup>th</sup> day of the whole experimental period which was further analyzed for liver function tests. Blood serum was prepared by centrifugation at 4000 rpm for 15min at 4°C [20]. After the completion of present experimental period, all animals were sacrificed and target organ i.e., liver was removed, rinsed with cold normal saline (0.9% sodium chloride) [20], dried on blotting paper and noted their weights separately. Relative body weight was measured on the basis of 100 g.

### Serum Hepatic Markers

Serum hepatic function tests involves the assessment of marker enzymes including aspartate transaminase (AST), alanine transaminase (ALT), alkaline phosphatase (ALP), total protein (TP) and albumin which were performed through automated biochemical analyzer (Microlab-300, Merck) using standard commercially available kits.

### Histopathological Analysis

Small portion of 10% formaline preserved liver specimens were taken, dehydrated by passing through graded series (70-100%) of ethanol, cleaned with xylene, embedded in paraffin and finally 5-6 um thin sections were prepared through microtome. The hepatic sections were stained through heamatoxyline and eosine (H and E) according to standard procedure [21].

### Data Analysis

The data was subjected to statistical analysis using Origin 9 (OriginLab Corp) by means of one-way analysis of variance followed by Duncan's post hoc test. Data was expressed as mean of three replicates±SE. A *p* value<0.05 was considered as significant.

## Results and Discussion

### Feed Nutritional Composition

Nutritional analysis of rabbit's feed revealed that values of moisture, total ash, fat, protein, fiber content

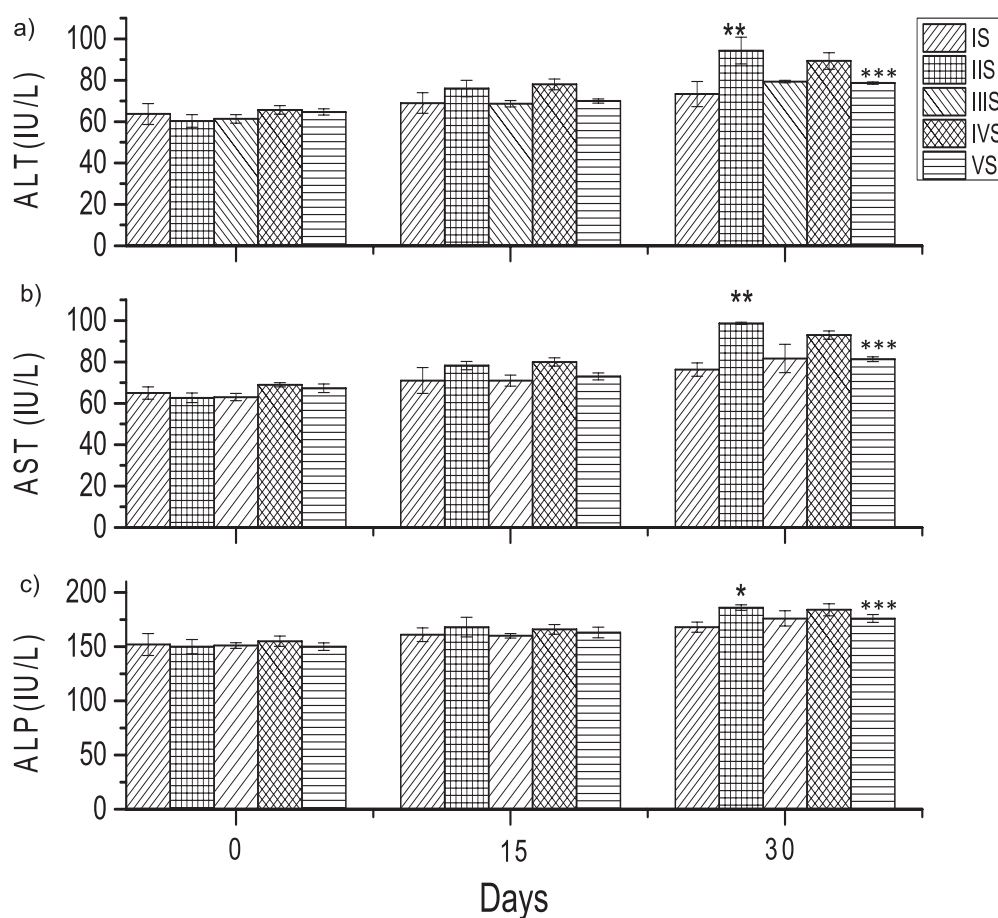


Fig. 2. Variations in hepatic enzyme markers in treated rabbits: a) Hepatic enzyme Alanine Aminotransferase (ALT) alterations b) Hepatic enzyme Alanine Aminotransferase (AST) changes c) Hepatic enzyme alkaline phosphatase (ALP) alterations on flonicamid exposure and ameliorative effects on co-administration of vitamins supplementation. Values are mean ± SE of five replicates. Significant at  $P > 0.05$ . \* Significant only. \*\* Highly significant from control. \*\*\* Highly significant from IIS group.

and carbohydrates are  $10.97 \pm 0.89$ ,  $1.62 \pm 0.13$ ,  $0.99 \pm 0.05$ ,  $11.95 \pm 0.245$ ,  $1.54 \pm 0.06$  and  $69.48 \pm 0.23$ , respectively. Present results showed that feed of rabbits provided all basic nutrients required for proper animal body growth.

#### Lethal Dose 50

Group II (50 mg/kg b.w) and III (100 mg/kg b.w) showed no mortalities whereas in groups IV (200 mg/kg b.w) and V (400 mg/kg b.w) 100 percent mortalities were observed. Animals of high dose level showed physical signs of toxicity such as diarrhea, tremors, prostrations and convulsions. In the present study four dosage levels ( $n = 4$ ) are used,  $D_a$  is 50 mg/kg b.w and there are three animals in each group ( $K = 3$ ). Then by applying the formula,  $LD_{50}$  was calculated which is 180 mg/Kg body weight. For further studies  $1/10^{th}$  of this value i.e., 18 mg/kg b.w was given to the rabbits orally for thirty days.

#### Body Weight and Relative Organ Weight Changes

During thirty days study period no mortalities were observed on oral administration of sublethal dose of flonicamid. Among the physical signs of toxicity, there was significant decrease of body weight gain in IIS group as compared to control, whereas the body weight

gain was observed in IIIS, IVS and VS groups which are supplemented with vitamins. Similarly, in beagle dogs, 90 days flonicamid (98.7% purity) oral toxicity studies were carried out by Low and Lambre [22]. They reported the clinical signs of toxicity consisted of decreased body weight, ataxia, vomiting, prostration, laboured breathing at 20 mg/kg b.w/day in both male and female dogs as compared to control. Body weight reduction was directly connected with rejection of feed.

Results showed that vitamin C given alone in IIIS group better protects the animal body on weight reduction as compared to IVS where vitamin E was given alone. In group VS, co-administration of vitamin E and C showed very good results in protecting body weight reduction as compared to IIS group (shown in Fig. 1a). In the current results there was a significant increase in liver weight of rabbits of IIS group administering with Flonicamid only in comparison to control (shown in Fig. 1b).

#### Hepatic Markers

Administration of sublethal dose of flonicamid showed toxic effects on liver tissues of exposed rabbits which altered the serum hepatic markers from normal level. There was a significant increase in ALT enzyme in IIS group at day 30 ( $94.33 \pm 6.4$ ) as compared

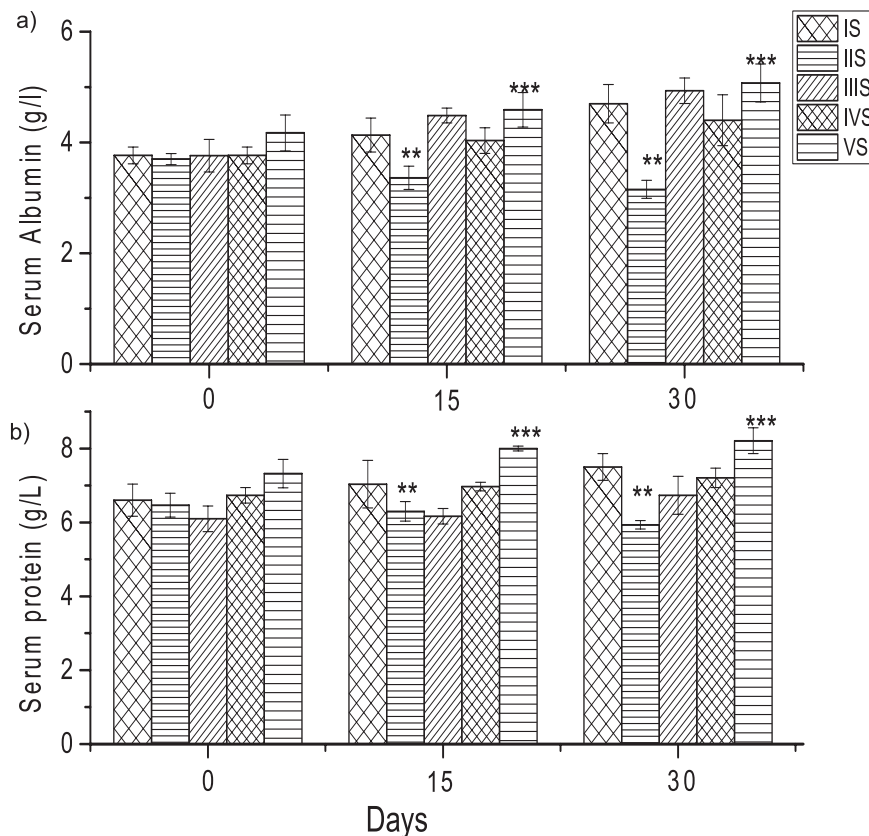


Fig. 3. Changes in serum protein content in flonicamid exposed rabbits and ameliorative effects on co-administration of vitamins supplementation: (a) Serum albumin content b) Total serum protein content. Values are mean  $\pm$  SE of five replicates. Significant at  $P > 0.05$ . \* Significant only. \*\* Highly significant from control. \*\*\* Highly significant from IIS group.



to control IS ( $73.33 \pm 6.11$ ). However the use of vitamin C/vitamin E shield the liver marker enzymes to increase at abnormal level as shown in Fig. 2a). Similarly at the day 30 of current study, AST and ALP enzymes showed high values in IIS group ( $98.66 \pm 0.57$ ,  $186.33 \pm 2.51$ ) in comparison to control ( $76.33 \pm 3.21$ ,  $168.66 \pm 4.72$ ), respectively. This raised level of enzymes was regulated to near to normal values on co-administration of both vitamin C and E (shown in Fig. 2(b,c)). This increase in ALT, ALP and AST enzymes may be associated with the loss of hepatic membrane architecture due to flonicamid toxic effects which contribute to the leakage of intracellular enzymes in to blood [11]. Our results are in accordance to Ahmed et al. [23], reported the elevated level of blood enzymes (ALT and AST) on pyrethroids exposure in rabbits. Similarly, Ismail [11] reported the increased level of hepatic enzymes (ALT, AST, ALP and gGT) on malathion exposure in rats as compared to control group and these activities were reduced near to control values

when rats were treated with malathion plus vitamin C. In wistar rats an oral 28 days flonicamid (98.7% purity) toxicity studies were performed by Low and Lambre [22]. They reported the decrease level of ALT in blood of male rats on 353 mg/kg b.w./day flonicamid oral administration through diet. These results are contradictory to present findings where ALT level was increased in the blood of rabbit on flonicamid exposure. In case of IIS, IVS and VS group, where vitamins were co-administered with flonicamid, the raised value of hepatic enzymes were decreased near to values of control group. Current results indicated that vitamin C and E alone as well as in combination, protected the liver cells from damage caused by flonicamid toxicity. These results are in concordance to several studies reported that vitamin C alone and in combination with vitamin E could reduce the lipid peroxidation by reducing the excessive production of reactive oxygen species generated due to pesticide exposure [18, 19].

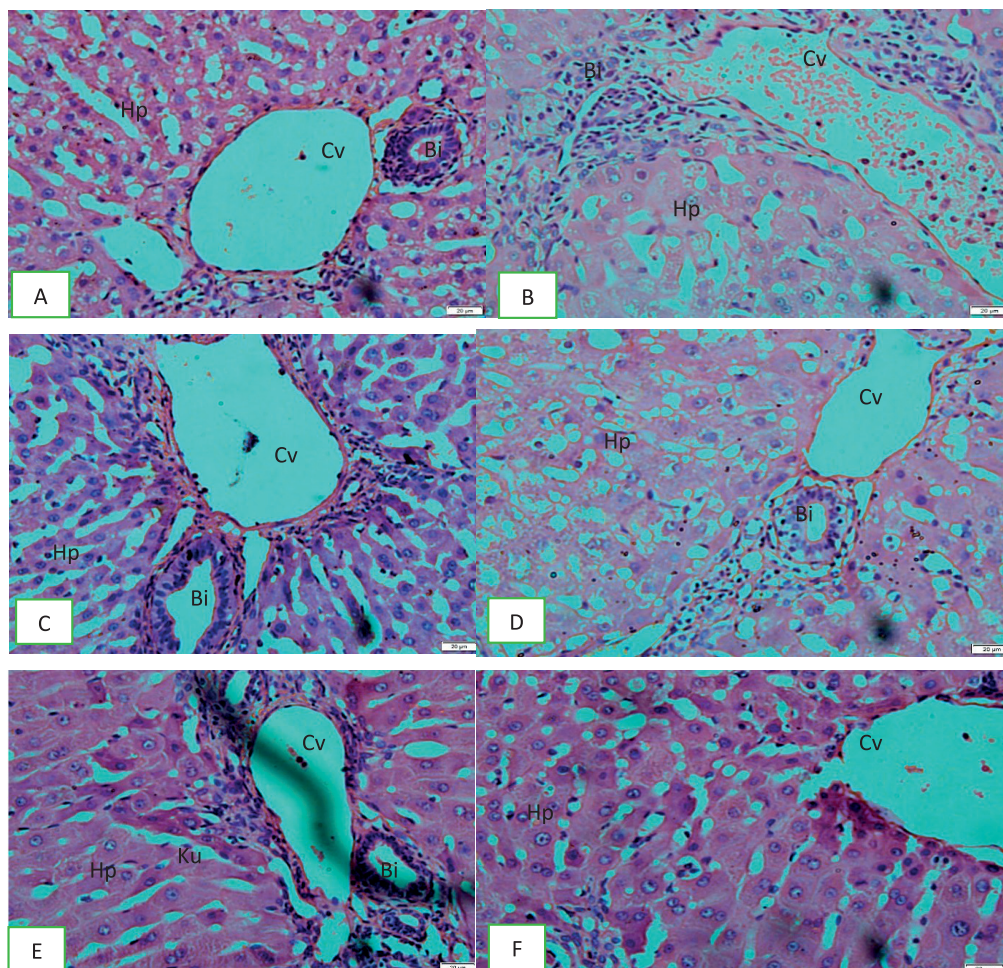


Fig. 4. Histological sections of liver of treated and control rabbits: a) a normal histological section of control (IS) exhibiting normal hexagonal hepatocytes (Hp), Centrilobular vein (Cv) and bile duct (Bi). b) a section of liver of rabbits of group IIS exhibiting sever dilated Cv and high infiltration of blood cells c) and d) sections of rabbit liver of group IIIS and IVS showing protective effects of vitamin C and E towards regeneration of parenchyma cells, respectively. e) and f) sections of rabbit liver of group VS showing normal hepatocytes and Kupfer cells (Ku), mild dilated Cv with regenerating cells associated with ameliorative effects of co-administration of both vitamin C and E.

On the other hand, serum total protein and albumin concentration were decreased on day 30<sup>th</sup> of study period in IIS group (5.93±0.11 & 3.15±0.16) in equated to IS (7.5±0.36 & 4.7±0.34), IIIS (6.73±0.51 & 4.93±0.23), IVS (6.9±0.26 & 4.4±0.45) and VS (7.04±0.36 & 5.07±0.34) respectively as presented in Fig. 3(a,b). Total protein and albumin content were significantly decreased in IIS group indicating the disturbance of amino acid anabolic pathways due to hepatocellular injury [11] caused by fonicamid. These results are in agreement with various studies [11, 24] reported the decrease in serum protein content on different pesticides exposure and supplementation of non-enzymatic antioxidants (vitamin C and E) protect the body from amino acids oxidation.

### Histological Analysis of Hepatic Tissues

Microscopic studies of stained liver tissue sections of rabbits showed altered histology of hepatocytes intoxicated with fonicamid. Histological inspection of liver tissues of control rabbits (IS group) depicted normal architecture of hepatocytes having hexagonal shape with normal vesicular nuclei, uniform cytoplasm, arranged in anatomizing cords, radiating from central vein to the normal portal triad and separated from each other by blood sinusoids (Fig. 4). Rabbit's liver tissue of IIS group exhibited severe dilated central vein and portal triad as well as high infiltration of leukocytes. These results are in corroboration to Low and Lambre [22] reported the infiltration of lymphocytes and hepatocellular hypertrophy on oral administration of fonicamid at 353 mg/kg bw/day in male rats. However, the toxic effects of fonicamid on hepatocytes histology was reduced in IIIS and VS group exhibiting mild dilated central vein and portal triad. In the case of IVS group, there were moderate alterations in rabbit liver cells showing modest dilation of portal triad and sinusoid along with central vein hypertrophy with few leukocytes infiltration. These findings are correlated with Khaldoun [20], they reported that rats exposed to Emamectin benzoate co-treated with vitamin C showed reduction of necrosis and restoration of normal architecture of hepatocytes.

Animal toxicity study with sub lethal doses of fonicamid for 30 days may exhibit the picture that how human population exposure to low doses for a long time period may causes adverse effects on their health. A big limitation of this study is sacrifice of all treated animals at the end of study period due to which it is difficult to use these animals for substantial testing of other chemicals. A relatively large number of experimental animals are used in toxicity testing which raises ethical issues regarding reduction of animals. Fonicamid mode of action is still unknown and its exposure to animals may cause oxidative stress, enzymatic imbalance leading towards metabolic disorders and carcinogenicity are some aspects where future research is needed.

### Conclusion

In conclusion, determination of fonicamid acute oral LD<sub>50</sub> may help the agriculturist/farmer to realize the fatal dose exposure level of this insecticide. The dietary supplementation of vitamin C and E in fonicamid exposed rabbits ameliorates abnormal changes of hepatic plasma markers, serum protein content and restore the normal histology of hepatocytes by reducing the oxidative stress leading towards the toxicopathic effects of fonicamid.

### Acknowledgment

The corresponding author of this manuscript acknowledges the role of Dr. Yasar and Dr. Ijaz Ahmad at PCSIR labs complex, Lahore for providing laboratory and animal house facilities to undertake this study.

### Conflict of Interest

The authors declare no conflict of interest.

### References

1. GARZON A., MEDINA P., AMOR F., VIÑUELA E., BUDIA F. Toxicity and sublethal effects of six insecticides to last instar larvae and adults of the biocontrol agents *Chrysoperla carnea* (Stephens) (Neuroptera: Chrysopidae) and *Adalia bipunctata* (L.) (Coleoptera: Coccinellidae). *Chemosph.* **132**, 87, **2015**.
2. KHAN M.I., SHOUKAT M.A., CHEEMA S.A., ARIF H.N., NIAZI N.K., AZAM M., BASHIR S., ASHRAF I., QADRI R.J.P.J.O.A.S. Use, Contamination and Exposure Of Pesticides In Pakistan: A Review. *Pak. J. Agri. Sci.* **57**, 131, **2020**.
3. SANKAR P., TELANG A.G., MANIMARAN A. Protective effect of curcumin on cypermethrin-induced oxidative stress in Wistar rats. *Experi. Toxicol. Path.* **64**, 487, **2012**.
4. NISTOR N., FRASINARIU O.E., STREANGA V. Acute poisoning with neonicotinoid insecticide. In *Poisoning - From Specific Toxic Agents to Novel Rapid and Simplified Techniques for Analysis*, Ntambwe Malangu, Intech Open. **107**, **2017**.
5. BONTE M., SAMIH M.A., DE CLERCQ, P. Development and reproduction of *Adalia bipunctata* on factitious and artificial foods. *BioCont.* **55**, 485, **2010**.
6. TAYLOR-WELLS J., GROSS A.D., JIANG S., DEMARES F., CLEMENTS J.S., CARLIER P.R., BLOOMQUIST J.R. Toxicity, mode of action, and synergist potential of fonicamid against mosquitoes. *Pesticide biochem. and physiol.* **151**, 3, **2018**.
7. MORITA M., YONEDA T., AKIYOSHI N. Research and development of a novel insecticide, fonicamid. *J. Pesticide Sci.* **39**, 179, **2014**.
8. ALI Z.Y. Neurotoxic effect of lambda-cyhalothrin, a synthetic pyrethroid pesticide: involvement of oxidative stress and protective role of antioxidant mixture. *New York Sci. J.* **5**, 93, **2012**.

9. LI H., ZHONG Q., WANG X., LUO F., ZHOU L., SUN H., YANG M., LOU Z., CHEN Z., ZHANG X. The degradation and metabolism of chlorfluazuron and flonicamid in tea: A risk assessment from tea garden to cup. *J.Sci. of the total Enviro.* **754**, 142070, **2021**.
10. CHAUHAN N., JOSHI M., LITORIYA N., PARMAR K. Persistence of Flonicamid 50 WG in/on Paddy. *Pesticide Res. J.* **31**, 114, **2019**.
11. ISMAIL S.M.. Protective effects of vitamin C against biochemical toxicity induced by malathion pesticides in male albino rat. *J. Evolutionary Biol. Res.* **5**, 1, **2013**.
12. SUN Y., MA A., LI Y., HAN X., WANG Q., LIANG H. Vitamin E supplementation protects erythrocyte membranes from oxidative stress in healthy Chinese middle-aged and elderly people. *Nutri. Res.* **32**, 328, **2012**.
13. HFAIEDH N., MURAT J.-C., ELFEKI A. A combination of ascorbic acid and  $\alpha$ -tocopherol or a combination of Mg and Zn are both able to reduce the adverse effects of lindane-poisoning on rat brain and liver. *J. Trace Elem. in Med. and Biol.* **26**, 273, **2012**.
14. BAIG M.B., AHMAD S., STRAQUADINE G.S. Management of sustainable rural development in Pakistan: possible options. *Agri. Manag.* **12**, 155, **2010**.
15. MAGE R.G., ESTEVES P.J., RADER C.J.D., IMMUNOLOGY C. Rabbit models of human diseases for diagnostics and therapeutics development. *J. Develop. and Comp.Immunology* **92**, 99, **2019**.
16. PAEZ V., BARRETT W.B., DENG X., DIAZ-AMIGO C., FIEDLER K., FUERER C., HOSTETLER G.L., JOHNSON P., JOSEPH G., KONINGS, E. AOAC SMPR® 2016.002. **99**, 1122, **2016**.
17. WEIL C.S. Tables for convenient calculation of median-effective dose ( $LD_{50}$  or  $ED_{50}$ ) and instructions in their use. *J Biometrics.* **8**, 249, **1952**.
18. TAKHSHID M.A., TAVASULI A.R., HEIDARY Y., KESHAVARZ M., KARGAR, H. Protective effect of vitamins E and C on endosulfan-induced reproductive toxicity in male rats. *Iranian J med.Sci.* **37**, 173, **2012**.
19. OZDEN S., CATALGOL B., GEZGINCI-OKTAYOGLU S., KARATUG A., BOLKENT S., ALPERTUNGA B.J.T., HEALTH I. Acute effects of methiocarb on oxidative damage and the protective effects of vitamin E and taurine in the liver and kidney of Wistar rats. *Toxico. Indus Health.* **29**, 60, **2013**.
20. KHALDOUN OULARBI H., RICHEVAL C., LEBAILI N., ZERROUKI-DAOUDI N., BAHA M., DJENNAS N., ALLORGE D.J.H., TOXICOLOGY E. Ameliorative effect of vitamin C against hepatotoxicity induced by emamectin benzoate in rats. *Human Exper. Toxicol.* **36**, 709, **2017**.
21. FETOUI H., GAROUI E.M., ZEGHAL N.J.E., PATHOLOGY T. Lambda-cyhalothrin-induced biochemical and histopathological changes in the liver of rats: ameliorative effect of ascorbic acid. *Experi.Toxico. Path.* **61**, 189, **2009**.
22. LOW K., LAMBRÉ C. First draft prepared by K. Low and C. Lambré Health Evaluation Directorate, Pest Management Regulatory Agency, Health Canada, Ottawa, Ontario, Canada Dammartin-en-Goële, France. **2016**.
23. AHMAD L., KHAN A., KHAN M.Z. Cypermethrin induced biochemical and hepato-renal pathological changes in rabbits. *Intl.J.Agri.Biol.* **13**, 865, **2011**.
24. EL-ELA F.I.A., ABDEL-AZIZ A. Investigating the potential protective effects of natural product quercetin against imidacloprid-induced biochemical toxicity and DNA damage in adults rats. *Toxicol. Rep.* **6**, 727, **2019**.